



Morphological diversity of the corneal small fibers in patients with type 1 diabetes mellitus

Anna Bregovskaya¹, Maria Lukashenko², Evelina Kamaeva², Natalia Gavrilova^{2,3,4*}, Lidiia Soprun^{2,4}, Nyurguyana Grigoryeva⁵, Ivan Pchelin², Leonid P. Churilov^{2,3}

¹Almazov National Medical Research Centre, St. Petersburg, Russia

²St. Petersburg State University, St. Petersburg, Russia

³St. Petersburg Research Institute of Phthisiopulmonology, St. Petersburg, Russia

⁴St. Petersburg State University Hospital, St. Petersburg, Russia

⁵St. Petersburg State City Diabetics Centre, St. Petersburg, Russia

*Correspondence to

Natalia Gavrilova, Email:
fromrussiawithlove_nb@mail.ru, n.y.gavrilova@spbu.ru

Received 15 Nov. 2021

Accepted 31 Dec. 2021

Published online 17 Apr. 2022

Keywords: Diabetes mellitus type 1, Diabetic neuropathy, Confocal microscopy of the cornea, Nerve fibers, Nerve branching, Small fiber neuropathy

Abstract

Introduction: Diabetic neuropathy (DN) affects up to 50% of patients with type 1 diabetes mellitus (T1DM). Clinical manifestations include painful polyneuropathy with autonomic and orthostatic symptoms. Corneal confocal microscopy (CCM) is one of the promising non-invasive methods for DN evaluation and tracking the effectiveness of treatment.

Objectives: To perform the early diagnosis of DN in T1DM patients and describe the morphological changes in nerve fibers during the treatment process.

Patients and Methods: This prospective study included 77 T1DM patients and 42 healthy controls. All patients underwent CCM and electroneuromyography (ENMG). Twenty-five patients with T1DM and HbA1c 7-10% underwent strict glycemic control with the correction of insulin therapy and the subsequent CCM and ENMG investigations for the second time.

Results: In T1DM patients a decrease in the main nerve trunks with age was revealed, as well as an increase in corneal nerve tortuosity ($P < 0.05$). The number of branches of nerve fibers did not change with the increasing age ($P = 0.07$). After reaching T1DM compensation, patients underwent a course of alpha-lipoic acid therapy. Confocal microscopy of the cornea parameters did not undergo significant changes during therapy since significant positive dynamics were noted only in the tortuosity of nerve fibers ($P < 0.05$), which decreased by 11.8%.

Conclusion: In patients with T1DM, strict glycemic control, correction of insulin therapy, and courses of alpha-lipoic acid prescription help to reduce the morphological changes of small fiber neuropathy, which can be evaluated by the confocal microscopy of the cornea.

Citation: Bregovskaya A, Lukashenko M, Kamaeva E, Gavrilova N, Soprun L, Grigoryeva N, Pchelin I, P. Churilov L. Morphological diversity of the corneal small fibers in patients with type 1 diabetes mellitus. Immunopathol Persa. 2022;x(x):e31336. DOI:10.34172/ipp.2022.31336.

Introduction

According to the American Diabetes Association, type 1 diabetes mellitus (T1DM) is a multicomponent chronic disease that requires multifactorial strategies of continuous medical care to reduce the risk of complications (1). It is a major cause of blindness, kidney failure, cardiovascular diseases and limb amputations in the world, as well as reducing the lifespan and life quality of patients, causing, therefore, significant socioeconomic burden (2).

The most widespread type is diabetes mellitus type 2, which in 2017 affected more than 450 million people worldwide, with prevalence of 6059 cases per 100 000 people and these numbers continue to progress rapidly (3). T1DM, being much less common disease, with prevalence varies significantly between countries, accounting for 5 to 10% of

Key point

Confocal microscopy of the cornea can be a promising method for the diagnostic of the early stages of peripheral neuropathy in patients with type 1 diabetes mellitus.

all cases of T1DM and mainly occurs in the group of children 10-14 years (4). Etiological factors include genetic predisposition, environmental triggers, and autoimmune dysfunction, that lead to the endocrine dysregulation, insulin dependence and also the development of numerous multiorgan complications (5, 6).

One of the most common complications of diabetes mellitus is diabetic neuropathy (DN). This condition affects up to 50% of patients with T1DM during their lifetime and can lead to numerous complications, including



foot ulceration, microcirculatory abnormalities and limb amputations (7). DN can be described as a dysfunction of peripheral nerve fibers, both sensory and autonomic with the exclusion of other possible etiologic causes (8). Clinical manifestations include burning sensations and sensory complaints in the distal extremities, with the typical polyneuropathy “gloves and socks” pattern. In addition to the pain syndrome, a dysfunction of deep sensitivity, postural instability with a tendency to falls, impaired microcirculation and the appearance of ulcers, mainly in the lower extremities, may appear (9,10).

Given the extremely high prevalence and also the likelihood of asymptomatic DN, its early diagnosis is one of the most complicated issues in modern diabetology (11). Dyck et al described the following four criteria for the diagnosis of diabetic peripheral neuropathy (12):

1. The presence of symptoms of neuropathy
2. Neurological examination of the patient
3. Autonomic sensory/motor functional tests
4. The speed of conduction of electric impulses in the nerve fibers

Electroneuromyography (ENMG) is still the most important tool in T1DM diagnostics, however this method does not allow detecting early stages of the nerve fiber damage. Punch biopsy of the skin with the intraepidermal nerve fiber evaluation and sural nerve biopsy play the main role among the existing methods of very early T1DM diagnostics (13-15). These techniques are invasive, which is an obvious disadvantage in patients with diabetes and requires a histological laboratory with specially trained personnel (16).

Corneal confocal microscopy (CCM) became one of the most promising non-invasive methods for studying the diabetic small fiber neuropathy (17). The technique is based on the phenomenon of combining two optical beams by setting the focal length between the lens and the axis of the eye (18). As a result of the study large-format images of the central and peripheral parts of the cornea are obtained, which do not contain distortions, do not need additional staining and fixation (19). CCM allows to diagnose the processes of damage and repair in the corneal subbasal plexus. The obtained results are characterized by high accuracy and reproducibility, which can lead to the evaluate DN in the early stages, helps to choose treatment strategy and also control its effectiveness (20).

Objectives

The aim of the study was to perform the early diagnosis of DN in T1DM patients and describe the morphological changes in nerve fibers during the treatment process.

Patients and Methods

The study was performed at the Almazov National Medical Research Center (Saint-Petersburg, Russia) and the City Diabetes Center №1 (Saint-Petersburg, Russia).

The study group included patients with T1DM and

DN. The control group consisted of healthy people. The parameters of inclusion in the study were:

- Diabetes mellitus 1 type
- Age from 18 to 45 years
- Patients with type 1 diabetes and the presence of clinical and/or electrophysiological signs of DN.
- Glycated hemoglobin <10%
- The duration of type 1 diabetes is up to 10 years

Exclusion criteria from the study:

- Diabetes mellitus 2 type and other endocrine diseases
- The presence of neuropathy of non-diabetic origin (alcoholic, hypothyroid, toxic and post-traumatic)
- Renal replacement therapy
- The presence of degenerative-dystrophic diseases of the spine, systemic connective tissue diseases
- The presence of uncontrolled arterial hypertension or a change in hypotensive therapy for three months before inclusion in the study
- The presence of hypercholesterolemia uncontrolled by statins, or a change in statin therapy for three months prior to inclusion in the study
- The presence of varicose veins of the lower extremities
- The presence of anemia, hypothyroidism
- The anamnesis of laser vision correction, any surgical interventions on the cornea and its traumatic injuries
- The presence of keratoconus, keratoglobus
- The presence of severe concomitant pathology, potentially leading to metabolic disorders (cardiac, respiratory, renal insufficiency of any genesis and the presence of cancer in the anamnesis or at the time of inclusion of the patient in the study)

The age restriction also applies not only to the examined patients, but also to the control group to exclude age-related nerve changes

Data analysis

The study included patients with T1DM and DN, the control group consisted of healthy people (Table 1). All patients underwent CCM and ENMG of the lower extremities with the assessment of amplitude and conduction velocity of the tibial and peroneal nerves (20). Corneal nerve morphology was assessed in diabetic patients with HbA1c above target levels before and after the treatment.

Table 1. Group description

	T1DM patients	Control group
Female	48	33
Male	29	9
Total number	77	42
Median age, years	29 years (18.0; 45.0)	27 years (21.0; 45.0)
Median duration of diabetes mellitus	10 (5.0; 10.0)	-
Median glycated hemoglobin	6.9 (5.9; 10.0)	-

Twenty-five patients with T1DM and HbA1c 7-10% were selected from the total cohort of subjects. Patients in this group underwent strict glycemic control with correction of insulin therapy. The rate of decreasing level of glycated hemoglobin was 1% at three months. After reaching target values of glycated hemoglobin (HbA1c <7%) CCM and ENMG were repeated. After that, infusion therapy with alpha-lipoic acid (600 mg+ NaCl 0.9%, tablets alpha-lipoic acid 600 mg 1 per day) within 14 days followed by switching to tablet form for another three months was performed. After the completion of the treatment course, all patients underwent CCM and ENMG for the third time.

Data analysis

The analysis of the obtained data was performed with Microsoft Excel (Microsoft, USA), SPSS (IBM, USA) programs.

Results

In patients with T1DM and in the control group, gender differences in the morphology of the subbasal nerve plexus of the cornea were not obtained ($P=0.133$). A decrease in the number of main nerve trunks with age was revealed and additionally an increase in corneal nerve tortuosity was detected ($P<0.05$). Number of branches of nerve fibers did not change with increasing age of patients ($P=0.07$).

When comparing the corneal nerves structure in patients with T1DM with the control group, a decrease in the number of main nerve trunks ($P<0.001$), the number of their branches ($P<0.001$), as well as a significant increase in nerve tortuosity was seen ($P<0.001$). The severity of corneal nerve damage is directly proportional to the duration of diabetes ($P<0.001$) and the level of glycated hemoglobin ($P<0.05$).

ENMG was conducted for all patients of the studied group. The amplitudes of action potentials of tibial nerve and sural nerve showed no significant relationship with the branching of the corneal nerves and their tortuosity ($P=0.07$). However, a decrease in the number of main nerve trunks of the cornea subbasal nerve plexus was

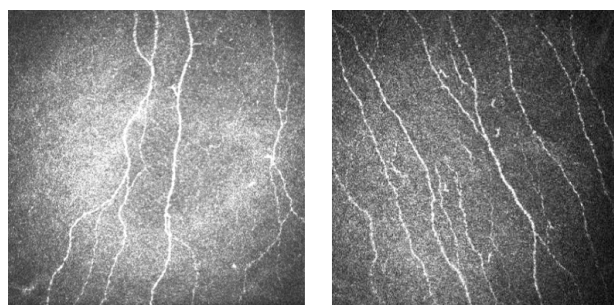


Figure 1. Corneal nerves before (1) and after (2) T1DM compensation.

closely correlated with a decrease in conduction velocity in both motor and sensory nerve fibers ($P<0.05$).

As a result, strict glycemic control contributed to an increase in the number of main nerve trunks by 16% ($P<0.001$), branching of nerve fibers increased by 32.4% ($P<0.001$), tortuosity decreased by 14.5% compared to the same parameters before T1DM compensation ($P<0.001$). A clearly positive dynamics of the corneal nerves state is shown in Figure 1.

More detailed results of the effect of T1DM compensation on the corneal nerves are presented in Table 2.

Reaching target values of glycated hemoglobin and blood glucose levels have provided a significant increase in the conduction velocity and amplitude ($P<0.001$). Amplitude values of tibial nerve increased by 9.9%, and sural nerve by 8.5%, conduction velocity tibial nerve increased by 4% and sural nerve by 8.3% (Table 3).

After reaching clinical and laboratory criteria of T1DM compensation, patients in this group underwent a course of alpha-lipoic acid therapy, after that the final CCM and ENMG investigations were conducted. CCM parameters did not undergo significant changes during therapy with alpha-lipoic acid medication and significant positive dynamics was noted only in relation to the tortuosity of nerve fibers ($P<0.05$), which decreased by 11.8% (Table 4).

The data of the lower extremities ENMG were also analyzed. The results of the conduction velocity and amplitude parameters investigation are presented in Table 5.

Table 2. Dynamics of the cornea subbasal nerve plexus morphology before and after T1DM compensation

Parameter (mean \pm SD)	Before T1DM compensation	After T1DM compensation	P value
Number of major nerve fibers	3.78 \pm 1.03	4.25 \pm 0.84	<0.002
Nerve branching	4.72 \pm 2.55	5.62 \pm 2.34	<0.001
Tortuosity coefficient of nerve fibers	14.31 \pm 4.76	12.37 \pm 1.06	0.009

Table 3. ENMG data before and after T1DM compensation

Parameter (mean \pm SD)	Before T1DM compensation	After T1DM compensation	P value
Amplitude nervus tibialis	8.39 \pm 3.40	10.00 \pm 3.33	0.0001
Amplitude nervus suralis	12.47 \pm 5.78	13.99 \pm 5.64	<0.001
Conduction velocity of nervus tibialis	45.7 \pm 8.60	49.85 \pm 6.70	0.0003
Conduction velocity of nervus suralis	44.92 \pm 5.27	48.46 \pm 4.48	<0.001

Table 4. CCM characteristics in patients with T1DM after diabetes compensation and course of pathogenetic treatment for DN

Parameter (mean ± SD)	After T1DM compensation	After course of treatment with alpha-lipoic acid	P value
Number of major nerve fibers	4.21±0.85	4.38±0.96	0.231
Nerve branching	5.62±2.34	5.71±2.19	0.455
Tortuosity coefficient of nerve fibers	12.37±1.06	12.99±1.08	0.113

Table 5. ENMG data of the lower extremities after T1DM compensation and after DN treatment

Parameter (mean ± SD)	Before T1DM compensation	After T1DM compensation	P value
Amplitude nervus tibialis	10.23 ±3.06	10.8 ±2.7	0.376
Amplitude nervus suralis	14.41±6.25	14.58± 6.45	0.390
Conduction velocity of nervus tibialis	49.21±7.41	49.63±5.44	0.762
Conduction velocity of nervus suralis	48.77± 5.41	49.12 ±5.39	0.032

As described in Table 5, after the prescription of therapy, we can reliably speak of an insignificant (less than 1%) increase in the speed of conduction of a nerve impulse in sural nerve.

Discussion

The detection of small fiber neuropathy seems to be an important issue of the up-to-date clinical medicine. The dysfunction of the peripheral nervous system most often starts with the most unprotected, terminal nerve branches (A delta and C fibers), spreading in the skin, mucous membranes and internal organs. Diabetes mellitus seems to be one of the most common diseases in which peripheral nervous system dysfunction is observed, which leads to the progression of such symptoms as burning and tingling sensations, allodynia and also dysautonomia symptoms, especially, in the cardiovascular system. In the absence of the appropriate preventive measures and treatment, patients may develop large nerve fiber damage that can manifest in postural disorders, gait disturbances, numbness of the extremities and further progression of other neurological symptoms. The important role of cross immunoreactivity, intestinal microbiota, short-chain fatty acids and antimicrobial peptides produced by islet cells was revealed in the T1DM pathogenesis. Therefore, the study of the influence of small fiber neuropathy on the pathogenesis of T1DM should be continued, since only a deep understanding of their role in the development of autoimmune pathology will help to provide recommendations for reducing the incidence of T1DM in the population.

Conclusion

Identification and development of methods for non-invasive diagnostics of small fiber neuropathy seems to be one of the most important socio-economic issues in medicine. Confocal microscopy of the cornea is a promising method, which application in this area can significantly improve the prognosis and quality of life of

such patients. Its advantages include a non-invasiveness, relative simplicity of the study and the ability to repeat the procedure in the same area of the cornea. Relative disadvantages include the need to purchase a confocal microscope, employees training and accordingly the possibility of developing small fiber neuropathy only in certain areas of the body ("patchy type", non-length-dependent).

The results of the study conclude that the application of this diagnostic method can be an important factor in tracking the dynamics of the disease and the effectiveness of the prescribed therapy, especially the glycemic level control.

Limitation of the study

The main limitation of the study was the confirmation of the small fiber neuropathy in T1DM patients only with CCM, without the skin biopsy, which is a "golden standard" in such studies. The decision was made, based on the possibility of infectious complications, performing the invasive diagnostic in diabetes patients. Besides, the second CCM and ENMG analysis were performed for the 25 patients out of 77 due to technical limitations.

Authors' contribution

AB, NyG and ML were the principal investigators of the study. NaG, LS and EK were included in preparing the concept and design. IP and LPC revisited the manuscript and critically evaluated the intellectual contents. All authors participated in preparing the final draft of the manuscript, revised the manuscript and critically evaluated the intellectual contents. All authors have read and approved the content of the manuscript and confirmed the accuracy or integrity of any part of the work.

Conflicts of interest

The authors declare no conflict of interest.

Ethical issues

The research followed the tenets of the Declaration of Helsinki. The Local Ethical Committee of St. Petersburg State University (protocol No. 115-02-5 from 25.06.20) approved this study. Accordingly, written informed consent was taken from all participants before

any intervention. We confirm that all methods were performed in accordance with the relevant guidelines and regulations. Besides, ethical issues (including plagiarism, data fabrication, double publication) have been completely observed by the authors.

Funding/Support

The work was performed with the grant support of the Russian Federation represented by the Ministry of Education and Science of Russia, Agreement No. 075-15-2021-1012 dated September 29, 2021.

References

- American Diabetes Association. Introduction: standards of medical care in diabetes-2021. *Diabetes Care*. 2021;44(Suppl 1):S1-S2. doi: 10.2337/dc21-Sint.
- Sarwar N, Gao P, Seshasai SR, Gobin R, Kaptoge S, Di Angelantonio E, et al. Diabetes mellitus, fasting blood glucose concentration, and risk of vascular disease: a collaborative meta-analysis of 102 prospective studies. *Lancet*. 2010;375(9733):2215-22. doi: 10.1016/s0140-6736(10)60484-9.
- Khan MAB, Hashim MJ, King JK, Govender RD, Mustafa H, Al Kaabi J. Epidemiology of type 2 diabetes - global burden of disease and forecasted trends. *J Epidemiol Glob Health*. 2020;10(1):107-11. doi: 10.2991/jegh.k.191028.001.
- EURODIAB ACE Study Group. Variation and trends in incidence of childhood diabetes in Europe. *Lancet*. 2000;355(9207):873-6. doi: 10.1016/s0140-6736(99)07125-1.
- Desai S, Deshmukh A. Mapping of type 1 diabetes mellitus. *Curr Diabetes Rev*. 2020;16(5):438-41. doi: 10.2174/1573399815666191004112647.
- Hicks CW, Selvin E. Epidemiology of peripheral neuropathy and lower extremity disease in diabetes. *Curr Diab Rep*. 2019;19(10):86. doi: 10.1007/s11892-019-1212-8.
- American Diabetes Association. Consensus statement: report and recommendations of the San Antonio conference on diabetic neuropathy. *Diabetes Care*. 1988;11(7):592-7. doi: 10.2337/diacare.11.7.592.
- Feldman EL, Callaghan BC, Pop-Busui R, Zochodne DW, Wright DE, Bennett DL, et al. Diabetic neuropathy. *Nat Rev Dis Primers*. 2019;5:41. doi: 10.1038/s41572-019-0092-1.
- Pascuzzi RM. Peripheral neuropathies in clinical practice. *Med Clin North Am*. 2003;87:697-724. doi: 10.1016/s0025-7125(03)00013-0.
- Dyck PJ. Detection, characterization, and staging of polyneuropathy: assessed in diabetics. *Muscle Nerve*. 1988;11:21-32. doi: 10.1002/mus.880110106.
- Sima AA, Brown MB, Prashar A, Chakrabarti S, Laudadio C, Greene DA. The reproducibility and sensitivity of sural nerve morphometry in the assessment of diabetic peripheral polyneuropathy. *Diabetologia*. 1992;35:560-9. doi: 10.1007/bf00400485.
- Sima AA. Diabetic neuropathy--the utility of nerve biopsy. *Electroencephalogr Clin Neurophysiol Suppl*. 1999;50:525-33.
- Lauria G, Hsieh ST, Johansson O, Kennedy WR, Leger JM, Mellgren SI, et al. European Federation of Neurological Societies/Peripheral Nerve Society Guideline on the use of skin biopsy in the diagnosis of small fiber neuropathy. Report of a joint task force of the European Federation of Neurological Societies and the Peripheral Nerve Society. *Eur J Neurol*. 2010;17:903-12, e44-9. doi: 10.1111/j.1468-1331.2010.03023.x.
- Sène D. Small fiber neuropathy: diagnosis, causes, and treatment. *Joint Bone Spine*. 2018;85:553-9. doi: 10.1016/j.jbspin.2017.11.002.
- Ziegler D, Papanas N, Zhivov A, Allgeier S, Winter K, Ziegler I, et al. Early detection of nerve fiber loss by corneal confocal microscopy and skin biopsy in recently diagnosed type 2 diabetes. *Diabetes*. 2014;63:2454-63. doi: 10.2337/db13-1819.
- Tavakoli M, Marshall A, Pitceathly R, Fadavi H, Gow D, Roberts ME, et al. Corneal confocal microscopy: a novel means to detect nerve fibre damage in idiopathic small fibre neuropathy. *Exp Neurol*. 2010;223:245-50. doi: 10.1016/j.expneurol.2009.08.033.
- Wang EF, Misra SL, Patel DV. In vivo confocal microscopy of the human cornea in the assessment of peripheral neuropathy and systemic diseases. *Biomed Res Int*. 2015;2015:951081. doi: 10.1155/2015/951081.
- Pritchard N, Edwards K, Russell AW, Perkins BA, Malik RA, Efron N. Corneal confocal microscopy predicts 4-year incident peripheral neuropathy in type 1 diabetes. *Diabetes Care*. 2015;38:671-5. doi: 10.2337/dc14-2114.